

ORIGINAL RESEARCH ARTICLE

FREQUENCY OF SECOND MESIOBUCCAL CANAL IN PERMANENT MAXILLARY SECOND MOLARS AT  
A TERTIARY CARE CENTRE OF NEPAL

Sageer Ahmed<sup>1\*</sup>, Snigdha Shubham<sup>1</sup>, Kriti Shrestha<sup>1</sup>, Vanita Gautam<sup>1</sup>, Govind Kumar Chaudhary<sup>2</sup>

<sup>1</sup>Department of Conservative Dentistry and Endodontics, Universal College of Medical Sciences, Ranigaon, Bhairahawa, Nepal

<sup>2</sup>Department of Conservative Dentistry and Endodontics, Chitwan Medical College, Chitwan-10, Nepal

Received: 19 Jan, 2024

Accepted: 10 Mar, 2024

Published: 30 Mar, 2024

**Key words:** MB2; Magnification; Maxillary Second Molar; Ultrasonic.

*\*Correspondence to: Sageer Ahmed, Department of Conservative Dentistry and Endodontics, Universal College of Medical Sciences, Ranigaon, Bhairahawa, Nepal.*

Email: [sageer11@yahoo.com](mailto:sageer11@yahoo.com)

DOI: <https://doi.org/10.54530/jcmc.1473>

**Citation**

Ahmed S, Shubham S, Shrestha K, Gautam V, Chaudhary GK. Frequency of second mesiobuccal canal in permanent maxillary second molars at a tertiary care centre of Nepal. Journal of Chitwan Medical College. 2024;14(47):28-31.



Peer Reviewed

**ABSTRACT**

**Background:** The success of endodontic treatment relies on the precise identification of root canals followed by cleaning, shaping, and obturating the canals. Mesiobuccal root of maxillary second molar teeth present wide variations with regard to the number and type of root canals. The complexity of the root canal varies widely in different ethnic groups. The study aimed to determine the prevalence of second mesiobuccal canal (MB2 canal) in maxillary second molar.

**Methods:** A descriptive cross-sectional study was conducted at Department of Conservative Dentistry and Endodontics, Universal College of Medical Sciences, Bhairahawa. A total of 100 permanent maxillary second molar undergoing endodontic treatments were studied. After access cavity preparation ultrasonic tips and magnification loupes were used to open the subpulpal groove in a direction from first mesiobuccal (MB1) canal towards the palatal canal to locate the second mesiobuccal (MB2) canal. Radiovisiography (RVG) was taken to confirm the presence of MB2 canals.

**Results:** MB2 canals were detected in 52 teeth out of 100 teeth that were studied. It was found that the younger adult (18-35 years) tends to have a higher proportion of MB2 canals (65.6%) as compared to the middle-aged elderly (36-55years) in whom it could be identified only 33.4% of the time.

**Conclusions:** Based on this study, it can be concluded that the prevalence of MB2 canal in mesiobuccal root of the permanent maxillary second molar is high.

**INTRODUCTION**

Each human tooth has its unique root canal anatomy and it differs on the basis of age, location, races and/or different ethnic groups.<sup>1</sup>In majority of cases, the permanent maxillary second molar tooth has mesiobuccal, distobuccal and palatal roots with independent canals. Among them, mesiobuccal root may contain two distinct root canals.<sup>2-4</sup> Previous studies have indicated that the missed canal acts as reservoir for colonization, growth and proliferation of microorganisms which leads to intra-appointment flare-up, secondary endodontic infection and failure of endodontic treatment.<sup>5,6</sup>

Frequently utilized methods to study the root canal morphology are radiographic techniques,<sup>7</sup> decalcification,<sup>8</sup> sectioning,<sup>9,10</sup> ultrasonics combined with magnification and cone beam computed tomography.<sup>11</sup> The incidence of the MB2 canal has been reported to be as low as 18.6% in an in vivo study and as high as 95.2% in an in vitro study.<sup>12</sup>

Munce burs, round burs, composite finishing burs and ultrasonics has been used to trough out dentin in search of MB2

canal.<sup>13</sup> The use of ultrasonic tips may be more conservative and aids in selective dentin removal.

Magnification loupe increases the confidence level of the operator by improving the visibility of the working field.<sup>14</sup> The combination of ultrasonic and magnification has been mentioned as one of the convenient, safe, non-invasive and successful method in many literatures.<sup>15</sup>

There is little scientific literature available for root canal morphology of maxillary second molar in Nepalese populations.<sup>16</sup> The study aimed to determine the prevalence of second mesiobuccal canal (MB2 canal) in maxillary second molar.

**METHODS**

A descriptive cross-sectional study was conducted in the patients who attended for root canal treatment (RCT) in Department of Conservative Dentistry and Endodontics, UCMS, Bhairahawa after taking approval from Institutional review committee (UCMS/IRC/126/21). A total of 100 patients were

selected using non probability (purposive) sampling technique for the study in duration of 6 months (Feb 2023-July 2023). The sample size was calculated by using given formula.<sup>17,18</sup>

$$\begin{aligned}\text{Sample size (n)} &= z^2 \times p(1-p) / e^2 \\ &= 1.96^2 \times 0.5(0.5) / 0.1^2 \\ &= 96.04 \approx 100 \text{ sample size}\end{aligned}$$

Where,

Z=1.96 at 95% Confidence interval

p= 0.5 at 50% assumed prevalence

e= 0.1 at 10% margin of error

Inclusion and exclusion criteria were considered before selecting the patients for study. Patient of 18-55 years of age having permanent maxillary second molar with irreversible pulpitis (symptomatic/asymptomatic), pulpal necrosis, apical periodontitis (symptomatic/asymptomatic), acute or chronic periapical abscess and failed previous root canal treatment were included in the study. Patients with restricted mouth opening (<three finger breadths), severe periodontal or concomitant endo-perio lesion and non-restorable teeth were excluded from the study.

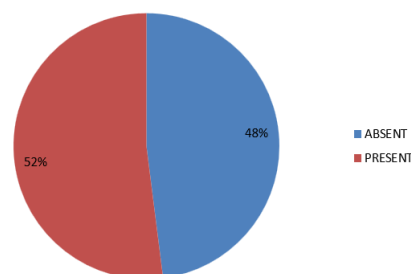
Access cavity was prepared in a triangular shape with a #2 or #4 size round bur with high-speed contra-angle handpiece maintaining aseptic environment. Furthermore, outline of the access cavity was modified with help of endo-z bur from a triangular to a rhomboidal shape to improve the visibility of the extra canal orifice. Upon the straight-line access, content of pulp chamber was flushed with 2.5% sodium hypochlorite and normal saline and the pulp chamber floor was explored for canal orifices. First mesiobuccal (MB1), distobuccal and palatal orifices were identified using endodontic explorer and scouted with small hand files (6 or 8 or 10 K-files). The identified canals were coronally flared with orifice shapers. If the second mesiobuccal canal (MB2 canal) could not be readily located, gentle troughing with ultrasonic tip (SB1, Woodpecker) was performed on the sub-pulpal groove at the expense of the mesial wall and 3mm long trough was prepared from MB1 canal towards the palatal canal. This developmental groove forms a line that connects the palatal and mesiobuccal canals and the orifice of second mesiobuccal canal is usually present on this groove or 1-2 mm mesial to it. The ultrasonic tip was applied at medium speed with light force under visualization of magnifying loupes. After at least 2 mm deep troughing of pulpal chamber floor, if the second mesiobuccal could still not be identified with DG16, then no further effort was made. This was done to prevent any inadvertent perforation. If MB2 orifice was identified, attempt was made to negotiate the canal with size 6, 8 or 10 K-files or C+ files in restricted canals. The presence and absence of MB2 canal was judged on the basis of Stropko's rule. Stropko considered a second mesiobuccal canal is present if he was simply able to instrument the canal to a depth of 3 to 4 mm from orifice level.

Routine root canal treatment was then performed which involved thorough shaping, cleaning and obturation of the root canal system followed by a definitive restoration.

Data were analyzed using SPSS (Statistical Package for Social Sciences, v. 22). The data was analyzed using measures of central tendency and measure of dispersion and presented in form of graph and table.

## RESULTS

The frequency of second mesiobuccal canal (MB2) found was 52% (Figure 1).



**Figure 1: Frequency of second mesiobuccal canal (N=100)**

The age of the patients was grouped into two groups as 18–35 years and 36–55 years and the frequency of MB2 canals were 38 out of 58 (65.6%) and 14 out of 42 (33.4%) respectively in two groups (Table 1).

**Table 1: Frequency of second mesiobuccal canal (MB2) in different age groups**

Age group	n (%)
18-35 years	58 (65.6)
36-55 years	42 (33.4)
<b>Total</b>	<b>100</b>

## DISCUSSION

Few studies have performed an exclusive evaluation of the configuration of root canals of the mesiobuccal root of the maxillary second molar, probably because it is assumed to be comparable to the mesiobuccal root of the maxillary first molar, where the MB2 canal is highly prevalent.<sup>19,20</sup> In vitro studies have shown higher frequency of MB2 canals than that of in vivo studies. Due to the limited access, visibility and non-constant location of the MB2 canal, there is always a risk of perforation that may reduce the frequency of two canals in the mesiobuccal root of maxillary second molars in clinical studies.

Studies have concluded, nearly 20.8% tooth had MB2 canal in maxillary second molar in Indian population, 34.39% MB2 canal in the Korean population and 18% MB2 in Chinese sub-population.<sup>21</sup>

The Nepalese population is generally considered to be a hybrid of several ethnic groups with characteristics of Caucasian, Mongoloid, and Negroid races, which is generally referred to as the Dravidian group. These mixed populations might be reasons of higher prevalence of MB2 canal. Such variability has been reported in a case series published in Nepal.<sup>16</sup>

In our study, the prevalence of second mesiobuccal canal was 52%, which is similar to the finding of other several studies.

Pablo et al., found 48% of maxillary second molar with MB2 canal in Chilean-specific population, using cone beam computed tomography (CBCT).<sup>22</sup> CBCT provides three-dimensional evaluation of tooth structure in various anatomical plane and helps in precise identification of MB2 as compared to two dimensional radiographs like RVG. Ng et al. reported 49% in Burmese population using a canal staining and tooth clearing technique.<sup>23</sup> Yoshioka et al. reported 44% in a Japanese study by using troughing under magnification in extracted teeth.<sup>24</sup>

Conversely, Alavi et al. found 41.5%, MB2 canal by using clearing technique in indigenous Thai population.<sup>25</sup> Pécora et al. reported 42% by using same technique in another study.<sup>26</sup> Although, clearing technique helps in a detailed and qualitative investigation of the delicate root canal systems, it has few drawbacks. There can be distortion in the morphology of the tooth as a result of the demineralization process. Moreover, the dyeing solution may not fully infiltrate into narrow canals and ramifications if the dimension is below the grain size of the injected dye. These might be reasons of lower frequency of MB2 in above studies.

Eskoz and Weine reported a frequency of 40% using endodontic files and periapical x-rays, a combined method to locate the MB2 canal.<sup>27</sup> The frequency may be fewer in this study due to lack of using magnification. Furthermore variation in skill levels and experience can influence the outcomes of studies.<sup>28</sup>

Other more specific techniques, such as the endodontic microscope and histology have attained prevalence of 95.8% and 100%, respectively.<sup>29</sup> Dental Operating Microscope (DOM) is considered gold standard tool of magnification in clinical patient based study due to its greater depth and area of visibility as compared to loupes. It provides more control and confidence to the operator in deeper troughing of coronal dentin which obstructs the patency of the canal. Similarly, histological analysis is considered gold standard in nonclinical ex vivo study as it allows both qualitative and quantitative evaluation of root canal anatomy.

The second mesiobuccal canals in maxillary permanent molars come under the category of hidden canals. In this study, additional techniques were employed to explore these hidden canals. Ultrasonic device was used to trough out dentin and uncover MB2 and magnification loupe was used to improve the illumination and depth of visibility.<sup>30-32</sup>

The age factor is also related to the prevalence of MB2 canal.<sup>33</sup> The patients in age group of 36–55 years showed less number of MB2 canals (33.4%) than patients of age groups 18–35 years (65.6%). As age advances, there are less chances of locating the second MB2 canals. It can be presumed that with age, the tooth is exposed to various insults like caries, attrition, erosion, etc., leading to calcification of the orifice or canal itself and deposition of secondary dentin and cementum causes further narrowing of root canal system. This is in accordance with other studies of Fogel et al. (1994) and Al Omer et al. (2000) which showed a significant inverse relationship between age and the occurrence of two canals.<sup>35,36</sup> Calcification of root canal begins from coronal portion while the apical portion of the canal remains patent in most of the cases. In two dimensional radiographs like RVG, it is not possible to get the impression of the narrow apical portion of the canal. Three dimensional radiographs like CBCT is needed to demonstrate such canals. In our study we used two-dimensional radiograph (RVG) and magnification loupes which might be reasons of failure to locate some of MB2 canals in elderly patients though they were apically patent.

The prevalence of MB2 canals in maxillary second molar teeth has been a subject of keen interest within the dental community, particularly in the context of the Nepalese population. A better understanding of this prevalence can lead to improved endodontic procedures and, ultimately, enhanced oral healthcare for Nepalese patients.

There were two major limitations in our study. Firstly, smaller population size was evaluated and secondly, CBCT and DOM were not used in this study. So, further research work is needed to get a generalized result by utilizing larger population and devices like CBCT and dental operating microscope.

## CONCLUSION

Based on this study, it can be concluded that the prevalence of MB2 canal in mesiobuccal root of the permanent maxillary second molar is high, so while performing endodontic therapy on maxillary second molars, the clinician should always look for MB2 canal, until proven differently. In addition, clinical use of magnification and ultrasonics device is needed to improve the success of endodontic treatment.

**CONFLICT OF INTEREST:** None

**FINANCIAL DISCLOSURE:** None

## REFERENCES:

1. Vertucci FJ. The endodontic significance of the mesiobuccal root of the maxillary first molar. *US Navy Med.* 1984; 63: 29-31. [\[PMID\]](#)
2. Badole GP, Bahadure RN, Warhadpande MM, Kubde RA. Rare root canal configuration of maxillary second molar: a case report. *Case Rep Dent.* 2012;76:75-82. [\[DOI\]](#)
3. Zhang R, Yang H, Yu X, Wang H, Hu T, Dummer PM. Use of CBCT to identify the morphology of maxillary permanent molar teeth in a Chinese subpopulation. *Int Endod J.* 2011;44:162- 169. [\[DOI\]](#)
4. Fogel HM, Peikoff MD, Christie WH. Canal configuration in the mesiobuccal root of the maxillary first molar: A clinical study. *J Endod.* 1994; 20:135-7. [\[DOI\]](#)
5. Imura N, Zuolo ML. Factors associated with endodontic flare-ups: A prospective study. *Int Endod J.* 1995;28(5): 261-5. [\[DOI\]](#)
6. Blattner T, George N, Lee C, Kumar V, Yelton C. Efficacy of Cone-Beam Computed Tomography as a Modality to Accurately Identify the Presence of Second Mesiobuccal Canals in Maxillary First and Second Molars: A

- Pilot Study. *J Endod.*2010; 36: 867-70. [\[DOI\]](#)
7. Pineda F, Kuttler Y. Mesiodistal & buccolingual roentgenographic investigation of root canals. *Oral Surg. Oral Med. Oral Pathol.* 1972; 33:101-110. [\[DOI\]](#)
  8. Ibarrola J, Knowles K, Ludlow M, Mickinley B. Factors affecting the negotiability of second mesiobuccal canals in maxillary molars. *J Endod.*1997; 23. [\[DOI\]](#)
  9. Pomeranz H, Fishelberg G. The secondary mesiobuccal canal of maxillary molars. *J. Am. Dent. Assoc.*1974;88:119-124. [\[DOI\]](#)
  10. Hartwell G, Bellizzi R. Clinical investigation of in vivo endodontically treated mandibular and maxillary molars. *J Endodon.* 1982; 8:555-7. [\[DOI\]](#)
  11. Betancourt P, Navarro P, Cantin M, Fuentes R. Cone-beam computed tomography study of prevalence and location of MB2 canal in the mesiobuccal root of the maxillary second molar. *Int J Clin Exp Med.* 2015;8(6):9128-34. [\[PMID\]](#)
  12. Kulild JC, Peters DD. Incidence and configuration of canal systems in the mesiobuccal root of maxillary first and second molars. *J Endod.*1990; 16:311-7. [\[DOI\]](#)
  13. Yoshioka T, Kikuchi I, Fukumoto Y, Kobayashi C, Suda H. Detection of the second mesiobuccal canal in mesiobuccal roots of maxillary molar teeth ex vivo. *Int Endod J.*2005;38:124-8. [\[DOI\]](#)
  14. Buhley LJ, Barrows MJ, Be Gole EA, Wenckus CS. Effect of magnification on locating the MB2 canal in maxillary molars. *J. Endod.*2002;28:324-327. [\[DOI\]](#)
  15. Wolcott J, Ishley D, Kennedy W, Johnson S, Minnich S. Clinical investigation of second mesiobuccal canals in endodontically treated & retreated maxillary molars. *J Endod.*2002;28; 477-9. [\[DOI\]](#)
  16. Nepal M, Gautam V, Subham S, Tripathi R, Sah R. An insight into anatomical variation in maxillary molars: Case series. *Journal of Universal College of Medical Sciences.* 2018; 6(2); 76-78. [\[DOI\]](#)
  17. Charan J, Biswas T. How to calculate sample size for different study designs in medical research? *Indian J Psychol Med.* 2013; 35(2):121-6. [\[DOI\]](#)
  18. Gharti A, Joshi N, Prajapati K, Wagle SD, Shrestha S. Extra canal in permanent maxillary first molar in patients undergoing root canal treatment at a tertiary care dental hospital, Nepal. *J Kathmandu Med Coll.* 2021;10(1):47-51. [\[DOI\]](#)
  19. Bauman R, Scarfe W, Clark S, Morelli J, Scheetz J, Farman A. Ex vivo detection of mesiobuccal canals in maxillary molars using CBCT at four different isotropic voxel dimensions. *Int Endod J.* 2011; 44: 752-758. [\[DOI\]](#)
  20. Abuabara A, Baratto-Filho F, Aguiar AJ, Leonardi DP, Sousa-Neto MD. Efficacy of clinical and radiological methods to identify second mesio-buccal canals in maxillary first molars. *Acta Odontol Scand.*2013; 71: 205-209. [\[DOI\]](#)
  21. Rosaline H, Kanagasabai A, Shaji, A, Bose S, Saeralathan S, Ganesh A. Analysis of root and canal morphologies of maxillary second molars in a South Indian population using cone-beam computed tomography: A retrospective study. *Endodontology.*2021; 33(3):133-138. [\[DOI\]](#)
  22. Pablo B, Pablo N, Ramon F. Cone-beam computed tomography study of prevalence and location of MB2 canal in the mesiobuccal root of the maxillary second molar. *Int J Clin Exp Med.* 2015;8(6):9128-9134. [\[PMID\]](#)
  23. Ng YL, Aung TH, Alavi A, Gulavibala K. Root and canal morphology of Burmese maxillary molars. *Int Endod J.* 2001; 34: 620-630. [\[DOI\]](#)
  24. Yoshioka T, Kikuchi I, Fukumoto Y, Kobayashi C, Suda H. Detection of the second mesiobuccal canal in mesiobuccal roots of maxillary molars ex vivo. *Int Endod J.* 2005; 38: 124-128. [\[DOI\]](#)
  25. Alavi A, Opananon A, Ng YL, Gulavibala K. Root and canal morphology of Thai maxillary molars. *Int Endod J.* 2002; 35: 478-485. [\[DOI\]](#)
  26. Pecora JD, Woelfel JB, Sousa Neto MD, Issa EP. Morphologic study of the maxillary molars. Part II: internal anatomy. *Braz Dent J.* 1992; 3: 53-57. [\[PMID\]](#)
  27. Eskoz N, Weine FS. Canal configuration of the mesiobuccal root of the maxillary second molar. *J Endod.* 1995; 21: 38-42. [\[DOI\]](#)
  28. Corcoran J, Apicella MJ, Mines P. The effect of operator experience in locating additional canals in maxillary molars. *J Endod.*2007; 33:15-17. [\[DOI\]](#)
  29. Schwarze T, Baethge C, Stecher T, Geurtsen W. Identification of second canals in the mesiobuccal root of maxillary first and second molars using magnifying loupes or an operating microscope. *Aust Endod J* 2002; 28: 57-60. [\[DOI\]](#)
  30. Al-Fouzan KS, Ounis HF, Merdad K, Al-Hezaimi K. Incidence of canal systems in the mesio-buccal roots of maxillary first and second molars in Saudi Arabian population. *Aust Endod J.* 2013; 39: 98-101. [\[DOI\]](#)
  31. Stropko JJ. Canal morphology of maxillary molars: clinical observations of canal configurations. *J Endod.* 1999; 25: 446-450. [\[DOI\]](#)
  32. Wolcott J, Ishley D, Kennedy W, Johnson S, Minnich S. Clinical investigation of second mesiobuccal canals in endodontically treated and retreated maxillary molars. *J Endod* 2002; 28:477-479. [\[DOI\]](#)
  33. Lee J, Kim K, Lee J, Park W, Jeong J, Lee Y, Gu Y, Chang S, Son W, Lee W, Baek S, Bae K, Kum K. Mesiobuccal root canal anatomy of Korean maxillary first and second molars by cone-beam computed tomography. *Oral Surg Oral Med Oral Pathol Oral Radiol Endod.*2011; 111: 785-791. [\[DOI\]](#)
  34. Zheng Q, Wang Y, Zhou X, Wang Q, Zheng G, Huang D. A Cone-Beam Computed Tomography Study of Maxillary First Permanent Molar Root and Canal Morphology in a Chinese Population. *J Endod.*2010;36: 1480-1484. [\[DOI\]](#)
  35. Fogel HM, Peikoff MD, Christie WH. Canal configuration in the mesiobuccal root of the maxillary first molar: A clinical study. *J Endod.*1994; 20:135-137. [\[DOI\]](#)
  36. Al Shalabi RM, Omer OE, Glennon J, Jennings M, Claffey NM. Root canal anatomy of maxillary first and second permanent molars. *Int Endod J.* 2000; 33(5):405-14. [\[DOI\]](#)